

## OVERVIEW

- **Tracheitis due to coronavirus infection in a three-month-old calf**
- **Abortion due to foetal infection with bovine parainfluenza 3 virus**
- **High pheasant poult mortality due to spironucleosis and adverse weather conditions**

## GENERAL INTRODUCTION

July was unsettled throughout and frequently cool, wet and windy. This is reflected in the climate statistics which, in comparison to the 1991-2020 period, show a mean temperature of 13.2°C (-0.3°C), 150 per cent of average rainfall and 91 per cent of average sunshine hours.

### DISEASE ALERTS

The following conditions were reported by SRUC VS disease surveillance centres in October 2022. Given similar climatic and production conditions, they could also be important this year.

- **Fog fever**  
Fog fever should be a differential diagnosis where there is a history of acute dyspnoea with minimal coughing in adult cattle following introduction to better grazing in the autumn. L-tryptophan in the grass is metabolised to 3-methyl indole within the rumen and absorbed into the bloodstream. This compound is pneumotoxic and triggers a potentially fatal interstitial pneumonia. All animals should be removed from the pasture following a diagnosis of fog fever.
- **Systemic pasteurellosis due to *Bibersteinia trehalosi***  
Diagnoses of systemic pasteurellosis due to *Bibersteinia trehalosi* peak during late autumn. Postmortem examination findings indicate septicaemia and there may be necrotic lesions in the pharynx, oesophageal ulceration or miliary foci in the liver. In 2022 a range of possible predisposing factors/concurrent issues were identified including recent gathering, hyposemelenosis and parasitic gastroenteritis.

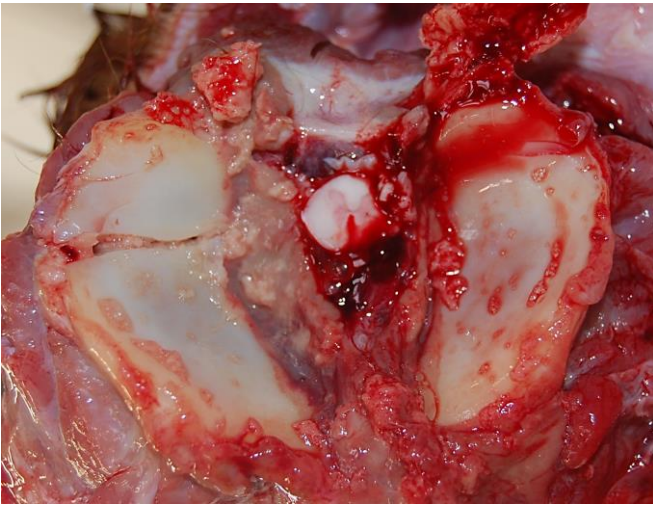
## CATTLE

### Parasitic diseases

Blood and faecal samples were collected to investigate an issue with poor body condition and profuse scour in a group of suckler cows. The affected animals were all second calvers and were reported to have been wormed in November 2022. Information on the product used was not supplied. The corresponding worm egg count/pepsinogen results for the four animals sampled were 200 eggs per gram (epg)/3.1 iu/l (reference range  $\leq$  1.5 iu/l); 400 epg/7.6 iu/l; 50 epg/3.8 iu/l; 200 epg/7.4 iu/l. There was evidence of hypoalbuminaemia in all cases with albumin results ranging from 21 to 26 g/l (reference range 30 – 40 g/l). These results were consistent with a diagnosis of ostertagiasis and suggested that the cattle had been grazing a field heavily contaminated with infectious nematode larvae.

### Generalised and systemic conditions

Five neonatal calves from a group of 80 spring calving beef cows were reported to have unilateral cloudy eyes. The submitted simmental cross calf was born to a heifer and required assistance to suckle. A cloudy eye was first observed when it was three days old. It was treated with a five-day course of antibiotics which resolved the ocular lesions. However, it failed to thrive and died at two weeks-of-age. The carcass was found to be poorly muscled with depleted body fat stores. Postmortem examination confirmed navel ill, septic arthritis affecting the atlanto-occipital joint (AOJ) and a fracture of the right articular facet of the atlas (Fig 1). A *Klebsiella/Raoultella* sp was isolated from both the AOJ and brain. Unfortunately, the umbilical cultures became overgrown with *Proteus* sp making it impossible to identify the underlying mixed coliform growth, which may have included *Klebsiella/Raoultella* sp. It was postulated that the spinal fracture had occurred in the periparturient period and had predisposed to infection of the AOJ following bacteraemia from the navel ill. Pain associated with the fracture and septic arthritis will have discouraged the calf from suckling leading to weight loss and death. The cause of the ocular lesions in the group remained unknown but hypopyon secondary to bacteraemia was considered a possible explanation.



**Figure 1 – Atlas fracture in a two-week-old suckled calf**

### Respiratory tract diseases

Several suckled calves from a group of 24 were reported to be coughing and examination of three live calves detected mucoid nasal discharge, upper respiratory noise and crackles over the cranial lung fields but no evidence of pyrexia. One calf died and an on-farm postmortem examination was carried out. Lung congestion and thick, possibly purulent froth in the trachea and larynx were described. *Pasteurella multocida* was cultured from the larynx and detected in lung tissue by PCR. Histopathology found a mild to moderate suppurative bronchopneumonia that was not severe enough to cause significant clinical signs. The trachea showed multifocal epithelial erosion and ulceration with a mixed infiltrate of lymphocytes, plasma cells and neutrophils in the lamina propria. These lesions were not consistent with acute bacterial tracheitis, and a viral aetiology was suspected. Bovine coronavirus (BCoV) had been detected in lung tissue by PCR, but its role in bovine respiratory disease is unclear.

Immunohistochemistry for BCoV confirmed the presence of viral antigen in tracheal epithelial cells but there was no staining in the lung section. Tracheal pathology has been described in calves experimentally infected with BCoV.<sup>1</sup> It was proposed that BCoV was the cause of the tracheal lesions in this calf but no definitive cause of death was established. It could not be proved if BCoV was the cause of coughing in the other affected calves.

### Reproductive tract conditions

A newly established dairy farm was stocked with in calf heifers that had been imported from Denmark over the previous few months. BVD, IBR and Salmonella vaccines were given on arrival. Three stillbirths and the birth of two small weak calves were reported within a short period. A foetus and placenta were submitted with no significant findings on postmortem examination. A

multiplex PCR test used to screen the liver for bovine herpesvirus 1 (IBR) returned a positive result for bovine parainfluenza 3 virus (PI3). Histopathology revealed a multifocal subacute to chronic pneumonia with changes suggesting ongoing repair following an episode of necrosis and inflammation. There was no evidence of a necrotising alveolitis/bronchiolitis typical of active PI3 infection. Immunohistochemistry carried out on lung demonstrated positive labelling for PI3 within phagocytic cells in the terminal airways. The findings confirmed foetal PI3 infection and indicated that it was in the reparative phase at the time of abortion. PI3 is not commonly diagnosed as a cause of bovine abortion but has been previously reported.<sup>2</sup> It was not possible to confirm whether or not this was a one-off case as there were no ongoing losses.

### Nervous system disorders

A two-month-old Limousin cross heifer became pyrexial and developed seizures before dying 48 hours later. It was grazing hill ground and ticks were noted on the carcass. Louping ill was suspected and confirmed on brain histopathology which revealed a severe mononuclear meningoencephalitis, characterised by perivascular cuffs, glial foci, neuronocrosis and neuronophagia, mainly within the midbrain and medulla. Louping ill is often considered to be primarily a disease of sheep, but cattle, goats, horses, deer, pigs, dogs, red grouse and humans are all known to be susceptible.

## SMALL RUMINANTS

### Generalised and systemic conditions

A flock that had lambed 1100 ewes reported a number of lamb deaths in different groups of sheep. The losses often coincided with gathering and handling. Some lambs died in the pens and others were found dead over the following 48 to 72 hours. Multiple interventions were carried out at handling including ear notching, paratuberculosis vaccination, application of a pour on, vitamin B12 injection and administration of mineral/vitamin and benzimidazole drenches. The history raised suspicions of copper drench inhalation however this proved not to be the case. A three-month-old Scottish blackface ewe lamb was examined postmortem and found to have fibrinous pleurisy and anteroventral lung consolidation. *Mannheimia haemolytica* was isolated from the lung, liver and spleen confirming *Pasteurella* pneumonia and septicaemia. PCR testing of spleen was positive for *Anaplasma phagocytophila* however the significance of this as a predisposing factor could not be confirmed. As the lambs had been on the hill for some time it was thought likely that exposure would have taken place earlier in the year and was therefore unrelated to the current deaths.

Three lambs from a group of 160 ewes with lambs at foot presented with submandibular swellings. Multivitamin and anthelmintic drenches had been administered three weeks prior to presentation. A sick and recumbent lamb was euthanased for postmortem examination which revealed unilateral multiloculated laryngeal abscesses with necrosis of the underlying pharyngeal tissues. The meninges appeared cloudy, and a small abscess was found within the left olfactory bulb. *Trueperella pyogenes*, *Fusobacterium necrophorum* and a *Bacteriodes* sp were isolated and are common isolates from areas of tissue necrosis. The lesions were considered to be sequelae to a dosing gun injury. This had previously been identified as an issue in the flock and investigation by the private veterinary surgeon had ruled out problems with equipment and handling facilities. Poor dosing technique was considered the most likely explanation.

Four, 15-week-old Texel lambs presented with sudden onset of bilateral soft tissue swelling under the jaw (Fig 2). The sheep had previously received an anthelmintic drench and were treated with antibiotics in case of dosing gun injury. They failed to respond, and a fine needle aspirate was carried out on two animals. Histopathological examination of two slides revealed a cell population consistent with a lymph node. A high proportion of lymphoblastic mature lymphocytes indicated a reactive process rather than neoplasia. Two months later the swellings had subsided with no effects on liveweight gain. The cause remained unknown.



**Figure 2** – Non-pathological lymph node enlargement in Texel lambs

### Respiratory tract diseases

The carcase of a Texel ewe from a flock of 800 was submitted to investigate the death of a number of sheep following short episodes of pyrexia and dyspnoea. Postmortem examination confirmed laryngeal chondritis with occlusion of the airway due to necrosis and abscessation of the right arytenoid cartilage. The diaphragm surrounding the oesophageal hilus was markedly thickened and haemorrhagic with haemorrhage also present within the caudal lung lobes. Histopathology confirmed acute haemorrhage plus acute and chronic myofibre degeneration with some mineralisation. These findings indicated mild damage to the muscle of the diaphragm prior to a fatal tear and haemorrhage<sup>3</sup>, secondary to increased respiratory effort caused by reduced airway lumen. Periacinar degeneration in the liver was consistent with circulatory failure and hypoxia.

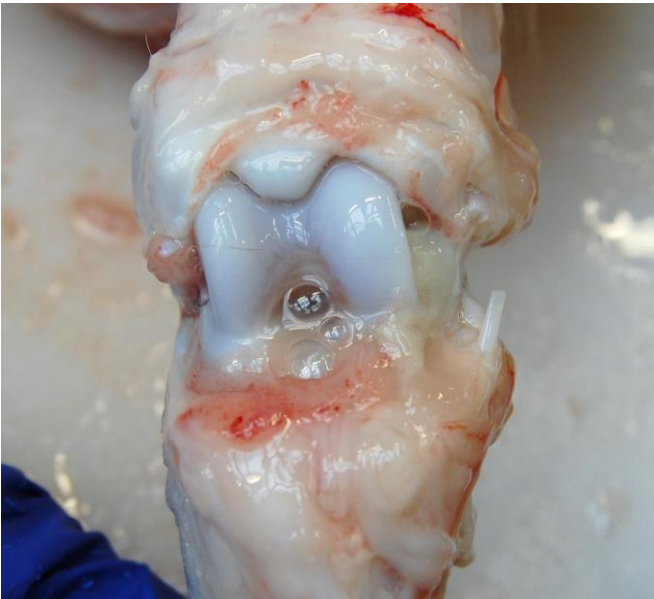
### PIGS

#### Generalised systemic diseases

A 580-sow breeding unit reported ill thrift in neonatal piglets with some diarrhoea pre-weaning and around 8 deaths each day. Problems with joint ill and meningitis had been seen post weaning. Three, three-week-old piglets were euthanased for investigation of the problem. Postmortem examination revealed purulent omphalophlebitis and diarrhoea in all cases. Rotavirus type A was detected by PAGE (pulsed agar gel electrophoresis) in two of the three piglets and histopathology was consistent with viral enteritis. A review of farrowing pen hygiene and assessment of passive colostral antibody transfer was suggested in addition to monitoring the number of enlarged umbilici in each litter. It was noted that clinical rotavirus infection is more common in piglets with concurrent disease, and that the health issues post weaning may also have their origins in failure of passive transfer and omphalophlebitis.

#### Musculoskeletal conditions

Multiple limbs were submitted from four pigs on a commercial unit with an increased incidence of lameness affecting 5 to 10 per cent of the weaners and 20 per cent of the finishers. The pathology varied from mild arthritis with a scant fibrinous component in the five to seven-week-old pigs (Fig 3), to more extensive involvement of the synovial membrane and significant serosanguineous joint effusion in the six-month-old pigs. *Streptococcus suis* type 2 was isolated from joints of the younger pigs and *Mycoplasma hyosynoviae* was detected by PCR/DGGE in synovial membranes from the finishers. Both were considered significant.



**Figure 3 – Septic arthritis due to *Streptococcus suis* Type 2 in weaned pigs.**

## BIRDS

### Game birds

A pheasant rearing enterprise purchased 3000 eight-week-old chicks in mid-July and divided them between three release pens that had been used in the two previous years without any issues. The birds looked fine on arrival and ate well for the first few days. Deaths began during two days of very wet, windy weather and bubbly diarrhoea was described. This improved but losses continued until one third of the birds had died and overall feed intake had fallen by 75 per cent. Six live birds were examined and were poorly muscled with prominent keel bones. They were euthanased and

found to have empty crops and enlarged gall bladders consistent with anorexia. The diarrhoea had resolved as reported but there was some evidence of urates and watery distal small intestinal contents. The birds were on medicated feed and only scant numbers of coccidial oocysts were detected in intestinal mucosal smears. Moderate numbers of motile protozoa were detected in the distal small intestine of one bird with scant numbers in a second. Histopathology confirmed enteritis consistent with spironucleosis. The high losses in this case were due to a combination of adverse weather and infection in birds that were stressed by the move to a new environment that they had not had time to adapt to. Incomplete feathering in this age of poult plus poor appetite in sick birds will have compounded the problem by rendering them susceptible to chilling and hypothermia once wet.

### References:

- 1 Park SJ, Kim GY, Chong HE, Hong YJ *et al*. Dual enteric and respiratory tropisms of winter dysentery bovine coronavirus in calves. *Arch Virol* 2007;152:1885-1900.
- 2 Macías-Rioseco M, Mirazo S, Uzal FA, Fraga M *et al*. Fetal pathology in an aborted Holstein fetus infected with bovine parainfluenza virus-3 genotype A. *Vet Pathol* 2019;56(2):277-281
- 3 Waine K, Strugnell BW, Howie F, Swainson V, Millar M, Diaphragmatic lesions and fatal haemorrhage in Texel sheep. *Vet Rec Case Rep* 2019;7:e000745. doi:10.1136/vetreccr-2018-00074

## SRUC VS Ovine Abortion Diagnoses 2023

This spring SRUC VS investigated the cause of abortion in 329 ovine submissions from 269 Scottish flocks. A further 174 submissions of ovine foetal material were received from 148 farms out with Scotland. The number of farms investigating cases of ovine abortion increased by 9 per cent compared to 2022.

A diagnosis was reached in 54 percent of submissions from Scottish flocks. This is an increase on 2022 when the overall diagnostic rate was 41 per cent. The diagnostic rate was 59 per cent in 185 submissions of foetuses +/- placentas examined at postmortem centres compared to 41 per cent for postal submissions. A diagnostic rate of 54 per cent in non-Scottish, and therefore primarily postal submissions, was similar to last year.

The breakdown of 2022 and 2023 abortion diagnoses is shown in Figure 1. Toxoplasmosis and enzootic abortion of ewes (EAE) were the most frequently made diagnoses in both years accounting for 37 per cent and 26 per cent of Scottish diagnoses this year. Toxoplasmosis was diagnosed in seventy Scottish flocks and toxoplasma vaccination history was provided for twenty-eight of these. Twenty-six flocks were unvaccinated but only one reported that this was because the vaccine was unavailable. A diagnosis of toxoplasmosis is made in a small number of vaccinated flocks each year and may be due to incorrect storage or administration of the vaccine.

Diagnoses of *Campylobacter* sp abortion in Scottish submissions increased from 8 to 14 per cent while the rate remained static at 21 per cent in non-Scottish submissions. The diagnosis not listed category includes sporadic bacterial causes of abortion including *Bibersteinia trehalosi*, *Arcanobacterium pluranimalium*, *Staphylococcus* sp and *Streptococcus* sp. There were no diagnoses of abortion due to Border disease made in Scotland this year and only two in foetuses from out with Scotland.

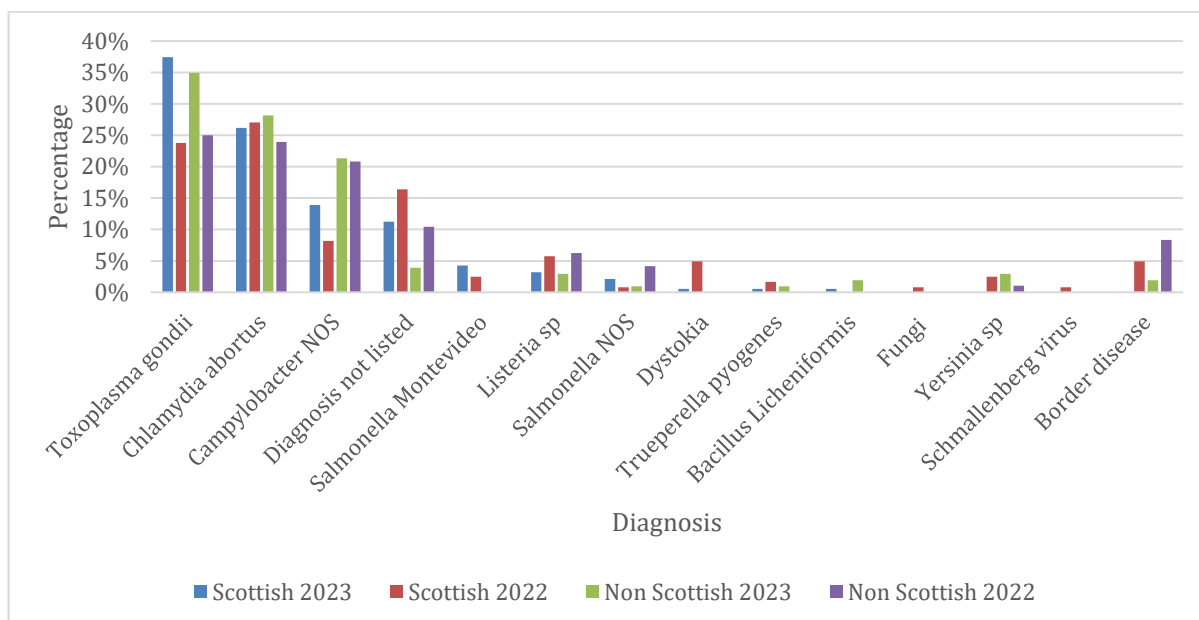


Figure 1 – SRUC VS ovine abortion diagnoses 2022 and 2023